

Early Arteriovenous Fistula Failure: A Logical Proposal for When and How to Intervene

Arif Asif,* Prabir Roy-Chaudhury,[†] Gerald A. Beathard[‡]

**Division of Nephrology, Section of Interventional Nephrology, University of Miami Miller School of Medicine, Miami, Florida; [†]Division of Nephrology, University of Cincinnati Medical Center, Cincinnati, Ohio; and [‡]Austin Diagnostic Center, Austin, Texas*

A significant number of arteriovenous fistulae (28 to 53%) never mature to support dialysis. Often, renal physicians and surgeons wait for up to 6 months and even longer hoping that the arteriovenous fistula (AVF) will eventually grow to support dialysis before declaring that the AVF has failed. In the interim, if dialysis is needed, then a tunneled catheter is inserted, exposing the patient to the morbidity and mortality associated with the use of this device. In general, a blood flow of 500 ml/min and a diameter of at least 4 mm are needed for an AVF to be adequate to support dialysis therapy. In most successful fistulae, these parameters are met within 4 to 6 wk. Most important, commonly encountered problems (stenosis and accessory veins) that result in early AVF failure can be diagnosed easily with skillful physical examination. Recent studies have indicated that a great majority of fistulae that have failed to mature adequately can be salvaged by percutaneous interventions and become available for dialysis. Early intervention regarding identification and salvage of a nonmaturing AVF is critical for several reasons. First, an AVF is the best available type of access regarding complications, costs, morbidity, and mortality. Second, this approach minimizes catheter use and its associated complications. Finally, access stenosis is a progressive process and eventually culminates in complete occlusion, leading to access thrombosis. In this context, the opportunity to salvage the AVF that fails early may be lost. This report reviews the process of AVF maturation and suggests a strategy for when and how to intervene to identify and salvage AVF with early failure.

Clin J Am Soc Nephrol 1: 332–339, 2006. doi: 10.2215/CJN.00850805

National Kidney Foundation Kidney Disease Outcomes Quality Initiative vascular access guidelines correctly rank the arteriovenous fistula (AVF) as the best available access for providing hemodialysis (1). It is for this reason that these guidelines and the Fistula First project recommend AVF creation in a majority of patients. However, a significant number of fistulae (28 to 53%) fail to mature adequately to support dialysis therapy (2–6). Frequently, these patients are consigned to a tunneled dialysis catheter for dialysis therapy. Although most modern catheters claim to provide adequate blood flow for dialysis, the United States Renal Data System has indicated that a significant number of patients do not receive adequate dialysis using this type of vascular access (7). In addition, tunneled catheters have been associated with the very high complication rates, rendering justification for their use more difficult as long-term dialysis access. In this context, early recognition and timely intervention in cases of an AVF with early failure are of critical value. The issue of early failure gains more importance as recent data have demonstrated that a great

majority of the failed fistulae can be salvaged using percutaneous interventions (5,8–11).

Although mechanisms of AVF maturation are complex and the exact timing of maturation is difficult to pinpoint, ample information exists in the literature regarding the general process (12–23). Nevertheless, the phenomenon remains poorly understood by many nephrologists as well as vascular surgeons. This report describes the current understanding of AVF maturation and early failure. In addition, it reviews blood flow and size changes that occur in a newly created AVF and presents information regarding when and how to intervene to identify and salvage fistulae with early failure.

Mechanisms of AVF Maturation

Why do some fistulae mature whereas others do not? To answer this question, one needs to understand the changes that occur at a hemodynamic, anatomic, molecular, and functional level after the creation of an arteriovenous anastomosis (12,20–43). The single most important determinant of all of the above and consequently of AVF maturation, however, is likely to be the response of both the feeding artery and the draining vein to the increase in shear stress that occurs after the creation of an arteriovenous anastomosis (12,20,24–26,35).

Shear stress is defined mathematically by the formula $4\eta Q/\pi r^3$, where η is blood viscosity, Q is blood flow, and r is vessel radius (24). At a conceptual level, the shear stress rate is an indicator of the difference in velocity between the center of the

Published online ahead of print. Publication date available at www.cjasn.org.

Address correspondence to: Dr. Arif Asif, Department of Medicine, Section of Interventional Nephrology, University of Miami, Miller School of Medicine, Miami, FL 33136. Phone: 305-243-3583; Fax: 305-243-3506; E-mail: aasif@med.miami.edu

vessel and the boundary layer, where, by definition, the blood velocity is zero. Thus, high-speed laminar blood flow will have a high shear stress rate, whereas low-flow multidirectional flow with eddies will have a low shear stress rate. The importance of shear stress in the pathogenesis of vascular stenosis, however, stems from the downstream mechanical and biologic impact of different levels of shear stress, especially in the context of a change in shear stress (20).

At a mechanical level, vessels try to maintain their original level of shear stress. An increase in blood flow and consequently shear stress (because shear is directly proportional to flow), after the creation of an AVF, will result in attempts to decrease the shear stress applied to the vessel wall. Because blood viscosity is difficult to alter, an increase in shear stress invariably results in vascular dilation (through biologic mediators; see below). This flow-mediated (shear stress) dilation increases vessel diameter and consequently brings the shear stress back to the prearteriovenous anastomosis level. This was demonstrated recently in an elegant study by Corpataux *et al.* (12). In this report, the impact of hemodynamic parameters on the remodeling of a newly created AVF was studied. Using echo-tracking and Doppler ultrasound techniques, vessel diameter, wall thickness, BP, and blood flow after the operation and at 1 and 3 mo of follow-up were measured. All recordings were performed in a controlled environment at 21°C. Within the first week, the blood flow increased to 539 ml/min (325 to 990), resulting in an increase in the mean shear stress to 24.5 dyn/cm² from its normal value of 5 to 10 dyn/cm², nearly a three-fold increase. This was accompanied by an increase in the internal diameter of the cephalic vein from its preoperative value of 2370 to 4430 μ m at 1 wk. The BP in the AVF remained unchanged throughout the study. However, the diameter of the vein increased to 5041 μ m by 4 wk and 6620 μ m at 12 wk. Because shear stress is inversely related to the diameter of the vessel, it gradually returned to the normal range (18.1 at 4 wk and 10.4 at 12 wk). A progressive change in the wall cross-sectional area in the cephalic vein was seen, increasing from 4.4 mm² at 1 wk to 5.3 mm² at 4 wk and 6.9 mm² at 12 wk ($P < 0.028$), indicating an increase in vascular mass. This seemed to be the result of vascular remodeling, resulting in an increase in internal diameter with no encroachment of the lumen by the process described by Mulvany *et al.* (23) (Figure 1).

At a biologic level, high shear stress rates (*e.g.*, those seen in the arterial circulation) result in endothelial cell survival (and quiescence), alignment of endothelial cells in the direction of flow, and the secretion of substances such as nitric oxide and prostacyclin that promote vasodilation and inhibit thrombosis and platelet aggregation (20,28,29,31,32). In marked contrast, low shear stress rates result in endothelial activation and the secretion of prothrombotic and vasoconstrictive substances such as thromboxane (35). Multiple studies clearly demonstrate that an increase in arterial flow rate and shear stress secondary to the creation of a distal AVF results in vascular dilation and a regression of neointimal hyperplasia (36–38). This increase in vascular diameter results in a normalization of shear stress. These experiments also demonstrate that normalization of shear stress (through closure of the distal AVF) results in a

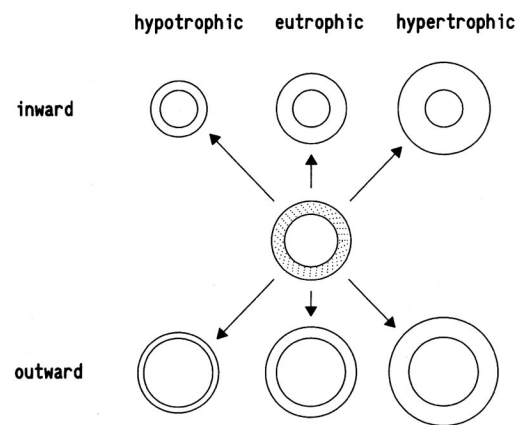


Figure 1. The diagram shows the manner in which remodeling can modify the cross-sections of blood vessels. The starting point is the vessel at the center (shaded). Remodeling can be hypertrophic (*e.g.*, doubling of cross-sectional area, vessels in the right column), eutrophic (no change in cross-sectional area, vessels in the center column), or hypotrophic (halving of the cross-sectional area, vessels in the left column). These forms of remodeling can be inward (*e.g.*, 30% reduction in lumen diameter, vessel in the top row) or outward (*e.g.*, 30% increase in lumen diameter, vessels in the bottom row). Reprinted from reference (23), with permission.

reduction of luminal diameter that is at least partly due to the accelerated formation of neointimal hyperplasia. At a biologic level, the vascular dilation that occurs as a result of an increase in shear stress seems to be mediated through an increased expression of nitric oxide (31–33). Inhibition of nitric oxide results in a diminution of the vasodilation that occurs after an increase in flow and shear stress (34). Matrix metalloproteinases also seem to play an important role in shear stress-mediated vascular dilation, perhaps through an enzymatic digestion of extracellular matrix components (39,40). Other authors have documented a role for TGF- β PDGF (41) and basic fibroblast growth factor (42) in this process. Ancillary studies in the setting of experimental abdominal aortic aneurysm models have also demonstrated macrophage apoptosis and an increase in antioxidative gene expression in response to an increase in shear stress (43,44). Finally, regardless of the exact biologic mediators involved, numerous studies have indicated that the vascular response to changes in shear stress is mediated through the endothelium, in that endothelial denudation abrogates this response (29,33).

It is important to point out, however, that all of the above studies focused on the arterial response to the creation of an AVF. Whereas numerous histologic studies have demonstrated medial hypertrophy in the venous limb of the AVF, there are almost no hard scientific data on the temporal pattern of vascular dilation that occurs in the vein in response to a flow-mediated increase in shear stress. It also should be noted that the medial hypertrophy that occurs in the draining vein in this setting would in fact reduce the vascular diameter and increase shear stress rather than reduce it back toward the pre-AVF level. This raises the question as to whether there are two

competing mechanisms that are operative after the creation of an arteriovenous anastomosis. Flow-mediated venous dilation brings the shear stress rate back toward its pre-AVF level, and pressure-mediated medial hypertrophy is completely independent of any shear stress–mediated changes. Clearly, we desperately need focused research in this area to document the hemodynamic, anatomic, and molecular changes that occur in the venous segment after the creation of an AVF.

On the basis of the above information, what are the possible biologic reasons for an AVF to undergo maturation failure? These are summarized as follows:

1. Failure of arterial dilation: The experimental studies described above clearly demonstrate that the creation of an AVF results in an increase in shear stress, which causes vascular dilation in an attempt to return shear stress levels back to normal. As we try to create AVF in patients with severe vascular disease and diabetes, however, it is possible that the conventional wisdom about the linkage between high shear stress rates and vascular dilation may not always hold true. In particular, the endothelium of a calcified vessel in an elderly uremic patient with diabetes may not have the ability to secrete the mediators that are required for flow-mediated vasodilation.
2. Failure of venous dilation: Similar reasons may also result in a failure of venous dilation. In addition, the aggressive push toward trying to create a native AVF whenever possible could result in the use of a poor venous segment that has lost the ability to vasodilate because of previous venipuncture. Genetic polymorphisms for mediators that favor either vasodilation or vasoconstriction also could play a role in both arterial and venous dilation/constriction.
3. Accelerated venous neointimal hyperplasia: (1) As a result of AVF configuration: There are many different configurations for the creation of an AVF, all of which may result in differing levels of shear stress at different points in the venous segment. In particular, there may be multiple areas of low shear stress at the arteriovenous anastomosis because of differences in compliance between the artery and the vein. These regions of low shear stress could result in focal areas of neointimal hyperplasia and vasoconstriction as occurs clinically in the context of the common juxta-anastomotic stenosis, which currently is the single most important reason for an AVF to fail to mature. (2) As a result of vascular injury: The segment that is most frequently affected with venous stenosis and is associated with early AVF failure is the segment that has been mobilized and manipulated by the surgeon during the procedure. This process often involves stretching, torsion, and skeletonization of the vessel. Skeletonization of the vessel may disrupt the vasa vasorum for that segment of vein. Whether these factors adversely affect the AVF and result in the lesions that are observed in this region is not clear; however, the possibility must be considered.

Early AVF Failure

In simple terms, an AVF that fails early is one that either never develops adequately to support dialysis or fails within

the first 3 mo of its use (8). In general, two variables are required for AVF maturation. First, the AVF should have adequate blood flow to support dialysis; second, it should have enough size to allow for successful repetitive cannulation. Although flow and size may appear as two separate parameters, they are intricately related.

Timing of Changes in Blood Flow and Diameter in a Newly Created AVF

Various studies have documented that the increments in blood flow begin to occur soon after the construction of an AVF in a great majority of cases (6,12–19) (Figure 2A). A recent report demonstrated changes in blood flow in an AVF after its construction (6). The authors investigated 50 radiocephalic fistulae. The results revealed a significant increase in blood flow from 20.9 ± 1.1 ml/min in the radial artery to 174 ± 13.2 ml/min in the AVF only 10 min after completion of the anastomosis. Using Doppler scanning determination of blood flow in another study of functioning autogenous radial-cephalic fistulae, blood flow increased to 754, 799, and 946 ml/min at 1, 7, and 42 d after AVF creation, respectively. Similar results were obtained by other investigators, who documented blood flow of 539 ± 276 and 848 ± 565 ml/min at postoperative day 1 and week 1, respectively (15).

Whereas the above-cited reports concentrated on blood flow augmentation in a newly created AVF, recent studies have focused on the changes in both blood flow as well as the diameter of an AVF postoperatively (14,16–19) (Figure 2). A prospective analysis of 152 successful radiocephalic fistulae found augmentation of AVF blood flow and cross-sectional area as early as 2 wk (16). This effect was seen both in younger (age 47.5 ± 11.5 [$n = 92$]; blood flow at 2 wk 750.4 ± 392.2 [SD]; cross-sectional area at 2 wk 11.5 ± 4.0 mm²) and older (age 71.8 ± 5.1 [$n = 60$]; blood flow at 2 wk 634.2 ± 310.3 ; cross-sectional area at 2 wk 10.4 ± 2.8) patients with an AVF. These findings were confirmed by Robbin *et al.* (19), who also found that major changes in the AVF blood flow and size occurred earlier on after AVF construction (diameter at 4 wk approximately 0.45 cm; blood flow at 4 wk approximately 700 ml/min) and that the two variables were essentially the same during the follow-up at 12 wk (diameter approximately 0.47 cm; blood flow approximately 675 ml/min). Most important, this study ($n = 69$) determined the minimum venous diameter and blood flow for predicting AVF outcomes. The results of the study revealed that a minimum venous diameter of ≥ 0.4 cm was associated with adequacy for dialysis in 67% of fistulae and a blood flow rate of ≥ 500 ml/min was associated with an adequate AVF in 70% of cases. When both variables were met, 95% of fistulae were adequate for dialysis. In this study, both a venous diameter of ≥ 0.4 cm and blood flow of ≥ 500 ml/min were seen during the first 2 months. Of particular interest, no significant changes in these two parameters were noted in the second, third, or fourth month after AVF creation. In contrast, multiple reports have demonstrated that a great majority of fistulae that did not achieve a significant increment in the two parameters within the first 6 to 8 wk failed

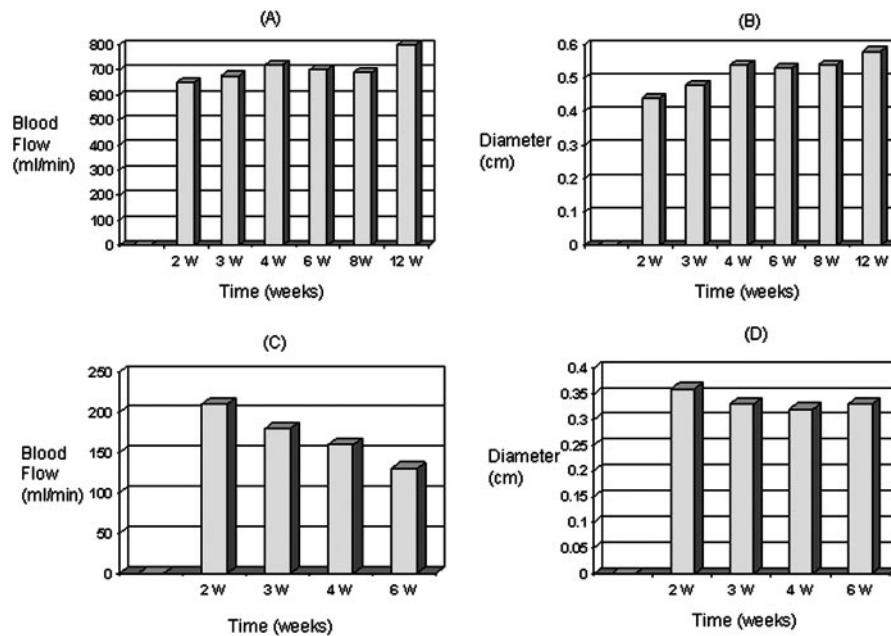


Figure 2. (A and B) Changes in blood flow and diameter in successful arteriovenous fistulae with time. (C and D) Changes in the two variables in fistulae with early failure. Adapted from references (12,14–19).

to mature adequately to support dialysis therapy (14,16–19) (Figure 2, C and D).

When to Intervene?

The above-cited studies establish that augmentation of flow and increments in the size of the vein in a successful AVF are early events. These reports also emphasize that AVF that are going to mature will do so within the first 2 to 4 wk. Therefore, good medical practice would suggest that an AVF should be evaluated for adequacy of development within the first 6 wk after its creation. The recommendation that this evaluation should be conducted at week 4 (Fistula First) or 4 to 6 wk after creation (8) is appropriate.

Two important issues highlight why the early identification and intervention approach is critical. First, a majority of fistulae with early failure demonstrate stenotic lesions within the access circuit (5,8–11). In addition, vascular stenosis is a progressive process. This is an important consideration, as the stenosis will eventually culminate in complete occlusion, leading to access thrombosis. In this context, the opportunity to salvage an early AVF failure may be lost. Second and perhaps more important, if a patient has an early AVF failure and has initiated dialysis therapy using a tunneled dialysis catheter, then he or she now is exposed to all of the complications related to catheter use. Hence, early intervention to identify and salvage early AVF failure becomes an important part of preventing AVF loss and minimizing complications related to tunneled dialysis catheters.

How to Intervene?

How to intervene in the case of an early AVF failure can be viewed in two components. One relates the interventions applied to identify candidates with early AVF failure; the other

component deals with the application of procedures to attempt salvage of such an access.

Interventions to Identify Candidates with Early AVF Failure

Fortunately, the identification of candidates with early AVF failure is relatively simple. As highlighted above, ultrasonography can identify successfully candidates who fail to meet the recently developed criteria for early AVF failure. However, this tool is not readily available in all centers, and its use adds to the cost of medical care. Recently, physical examination has been highlighted to be a valuable tool in assessing AVF with early failure (5,8,19,45,46) (Figure 3). In one study (19), experienced nurses were asked to evaluate AVF ($n = 30$) for maturation using physical examination. These patients also underwent ultrasound examination of the AVF for diameter and blood flow, but the nurses were blinded to the ultrasound results. The nurses then subjectively evaluated the maturity of the AVF and the usable length of the AVF for dialysis. The criteria included an easily palpable superficial AVF with adequate diameter for cannulation and a uniform thrill to palpation. The accessible draining vein needed to be relatively straight and at least 10 cm in length. On the basis of these criteria, the nurses were asked to predict whether the AVF would eventually mature. The findings of the assessment by nurses were recorded on a work sheet. On the basis of this physical examination, among the 21 AVF that they predicted would be adequate for dialysis, 17 (81%) achieved adequacy. In contrast, seven (78%) of nine of AVF that the dialysis nurses predicted would not be acceptable for dialysis were in fact inadequate. Thus, the overall accuracy of the prediction by an experienced examiner was 80% (24 of 30) in this study. This compared favorably with the 67 and 70% adequacy when only AVF diameter (≥ 0.4 cm) or blood flow (≥ 500 ml/min) on ultrasound is met, respectively. However,

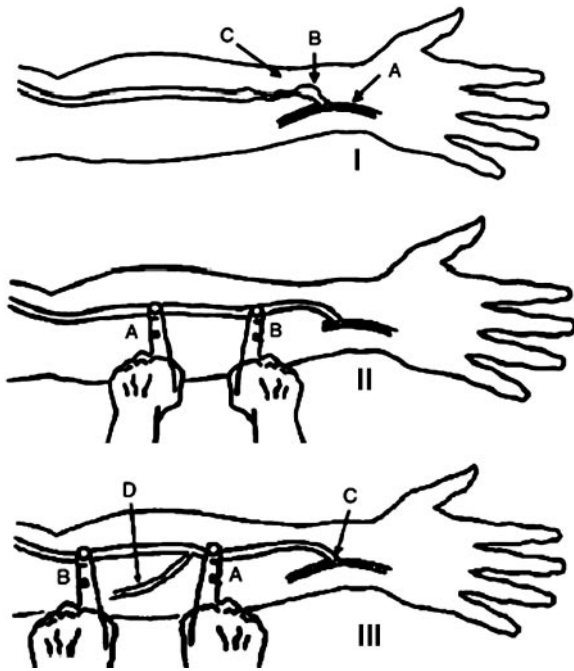


Figure 3. (I) Physical examination of juxta-anastomotic stenosis. (A) Radial artery. (B) A strong pulse is present at the anastomosis; the intensity of the thrill is variable but generally diminished as a result of decreased flow. The arteriovenous fistula (AVF) at this point may be dilated, at times almost aneurysmal. (C) The pulse disappears as one moves up the AVF to the level of the lesion. (II) Evaluation of pulse augmentation. The AVF first is completely occluded at point A. The change in pulse intensity (augmentation) is evaluated at point B. (III) Physical examination of accessory vein. When the AVF is occluded at point A, the thrill will disappear at the anastomosis (C). As the point of occlusion is moved upward past the accessory vein (D) to point B, the thrill will continue when the AVF is occluded because flow has an escape route. Reprinted from reference (45), with permission.

the adequacy of an AVF for dialysis reached 95% when both variables (diameter ≥ 0.4 cm and blood flow ≥ 500 ml/min) were met (19).

In contrast to its role in evaluating the maturation of an AVF, physical examination also can help in identification of candidates with early AVF failure. Beathard *et al.* (8) recently disclosed the two most common causes of an early AVF failure (presence of stenosis and/or accessory veins [discussed below]) and demonstrated that both can be diagnosed easily by physical examination. The value of physical examination in the identification of candidates with early AVF failure also has been demonstrated by a recent report (5). In this analysis, 68 fistulae were created and followed postoperatively by physical examination to assess their developmental progress. After the resolution of postoperative edema, physical examination was performed by an interventional nephrologist at 1- to 2-wk intervals. In this study, 24 (35%) of 68 fistulae failed to develop adequately to support dialysis. All were identified by physical examination within 8 wk of access creation.

Physical examination of the AVF is an important skill that

should be mastered by all nephrologists who treat dialysis patients. The normal mature AVF has a soft pulse and is easily compressible. There is a prominent thrill (hum, buzz) at the anastomosis that is present throughout the entire structure during systole and diastole. When the extremity is elevated, the AVF generally will collapse, at least partially. Typically, with juxta-anastomotic stenosis, a bounding pulse (water hammer) is felt at the anastomosis, and the thrill is diminished and shortened in duration (Figure 3I). As one moves downstream from the anastomosis, the pulse disappears at the site of the stenosis. Above this level, the pulse is very weak and the vein is usually poorly developed (Figure 3I). The strength of the pulse is directly proportional to the arterial inflow pressure and is assessed by the "pulse augmentation test" (Figure 3II). Although a subjective measure, this test can provide valuable information regarding the strength of arterial inflow when performed by an experienced examiner. It is performed by completely occluding the access several centimeters downstream from the arterial anastomosis and assessing the increment in the volume of the pulse by palpation. A normal AVF augments well, meaning that it has a very strong pulse and, by inference, a good arterial inflow. In contrast, the AVF that has a poor arterial inflow will be found to augment poorly, meaning a weak pulse. Accessory veins also can be identified easily by physical examination (Figure 3III). At times, they can be diagnosed by visual inspection only. On other occasions, examination by palpation is required to detect their presence. Occlusion of the outflow of an AVF normally results in disappearance of the thrill over the arterial anastomosis. If it does not disappear, then an accessory vein is present below the point of occlusion. Palpation of the AVF below this point will reveal the position of the accessory vein by the presence of thrill over its trunk. Finally, with downstream stenosis, the AVF becomes more forcefully pulsatile (hyperpulsatile) with a discontinuous and predominantly systolic thrill. When the extremity is elevated, the portion of the AVF distal to the stenosis remains distended while the proximal portion collapses in the normal manner. Swelling of the extremity is also an important physical finding. Persistent swelling of the upper extremity after AVF creation in itself is suggestive of central vein stenosis and deserves evaluation.

Actually, physical examination may be the most practical approach to the evaluation of AVF maturation and the identification of candidates with early AVF failure. From a practical standpoint, at a minimum, this evaluation should be undertaken between 4 and 6 wk by a skilful examiner. Any AVF that fails to mature adequately and demonstrates abnormal physical findings should be studied aggressively, and abnormalities that are detected should be corrected before a plan to create a new access is made (Figure 4).

Interventions to Salvage with Early AVF Failure

Once a patient with early AVF failure has been identified, appropriate action to salvage the AVF should be taken in a timely manner. Recent studies (5,8,9) demonstrated that the two most common problems observed in early AVF failure are the presence of stenosis and accessory veins. These studies have

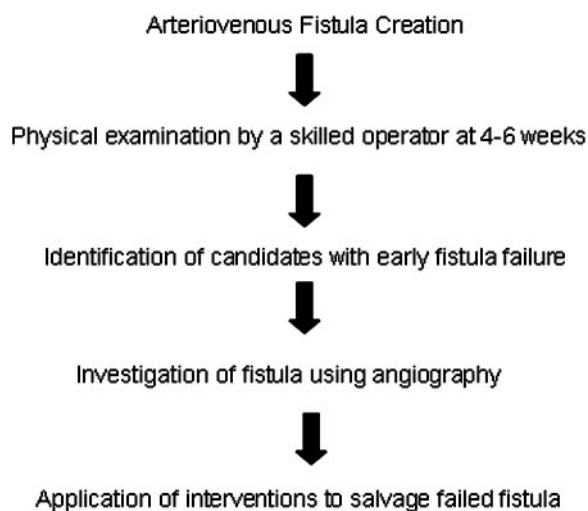


Figure 4. A simple algorithm for the evaluation of patients with early AVF failure. We recommend that this examination be performed at 4 to 6 wk. In addition to simple inspection, palpation for hyperpulsation, and isolated systolic thrill (45,46) in an AVF, arterial assessment must be performed (1,45,46). Manual compression and pulse augmentation test to evaluate inflow lesions (45) as well as inspection and palpation of the AVF for accessory veins (45) all should be conducted by a skillful operator.

emphasized that a great majority of these failed fistulae can be salvaged using percutaneous techniques. In a prospective observational study (8), 100 patients with early failure underwent evaluation and treatment at six free-standing outpatient vascular access centers. Vascular stenosis and the presence of a significant accessory vein (an accessory vein is described as a branch that comes off the main venous channel that comprised the AVF) alone or in combination were found to be the culprits in most instances. Venous stenosis was present in 78% of the cases. A majority (48%) of these lesions were found to be close to the anastomosis (a juxta-anastomotic lesion). A significant accessory vein was present in 46% of the cases. Percutaneous balloon angioplasty and accessory vein obliteration using one of three techniques (percutaneous ligation using 3/0 nylon, venous cutdown, or coil insertion) were used to salvage the failed AVF. Angioplasty was performed with a 98% and vein obliteration with a 100% success rate. After intervention, it was possible to initiate dialysis using the AVF in 92% of the cases. Actuarial life-table analysis showed that 84% were functional at 3 mo, 72% at 6 mo, and 68% at 12 mo. The overall complication rate in this series was 4%; of these, 3% were minor and 1% were major. All of these adverse events were associated with angioplasty procedures. The single major complication consisted of a vein rupture with an expanding hematoma. It resulted in loss of the access. The three minor complications all were hematomas that required no treatment and had no sequelae.

Using a percutaneous ligation technique, a separate report also described accessory vein ligation of fistulae that failed to achieve adequate blood flow or size for successful cannulation (9). In another analysis, Turmel-Rodrigues *et al.* (11) demon-

strated the successful application of endovascular techniques to salvage an AVF that had failed to mature.

By use of an aggressive approach and application of two basic techniques, balloon angioplasty and vein obliteration, nephrologists can salvage and subsequently use an otherwise failed AVF. Recent reports have highlighted a newer technique (sequential dilation) to salvage an AVF that fails to develop because of diffuse stenosis (5,47,48). In this technique, the AVF is gradually dilated with a progressively increasing size of angioplasty balloon at 2- to 4-wk intervals until a size that is optimal for dialysis cannulation is achieved.

In addition to endovascular techniques, surgical intervention has been used for AVF salvage (49,50). To the best of our knowledge, there is a lack of prospective studies that have examined the role of surgical approach in the salvage of AVF with early failure only. The creation of a new anastomosis for a juxta-anastomotic lesion and superficialization procedures are some of the techniques that are available in this category. Inability to navigate the wire across a stenotic lesion during percutaneous approach and deep location of an AVF are some of the indications for surgical intervention.

Conclusion

Data have documented that both an increase in size and blood flow augmentation occur within the first few weeks of an AVF creation in a great majority of cases. Consequently, the assessment of a newly created AVF and identification of candidates with early AVF failure should begin early. Physical examination provides a simple means for the identification of such candidates. Once identified, these patients then should be referred to an interventionalist for evaluation and appropriate intervention. Unnecessary delays may result in the delivery of dialysis with a tunneled dialysis catheter, rendering the patient susceptible to higher complications as well as morbidity and mortality.

Acknowledgments

This project was not funded by any grants or funding agencies.

References

1. NKF-K/DOQI clinical practice guidelines for vascular access: Update 2000. *Am J Kidney Dis* 37[Suppl 1]: S137–S181, 2001
2. Palder SB, Kirkman RL, Whittemore AD, Hakim RM, Lazarus JM, Tilney NL: Vascular access for hemodialysis. Patency rates and results of revision. *Ann Surg* 202: 235–239, 1985
3. Miller PE, Tolwani A, Luscly CP, Deierhoi MH, Bailey R, Redden DT, Allon M: Predictors of adequacy of arteriovenous fistulas in hemodialysis patients. *Kidney Int* 56: 275–280, 1999
4. Allon M, Lockhart ME, Lilly RZ, Gallichio MH, Young CJ, Barker J, Deierhoi MH, Robbin ML: Effect of preoperative sonographic mapping on vascular access outcomes in hemodialysis patients. *Kidney Int* 60: 2013–2020, 2001
5. Asif A, Cherla G, Merrill D, Cipleu CD, Briones P, Pennell P: Conversion of tunneled hemodialysis catheter con-

- signed patients to arteriovenous fistula. *Kidney Int* 67: 2399–2407, 2005
6. Won T, Jang JW, Lee S, Han JJ, Park YS, Ahn JH: Effects of intraoperative blood flow on the early patency of radiocephalic fistulas. *Ann Vasc Surg* 14: 468–472, 2000
 7. U.S. Renal Data System: *USRDS 2002 Annual Data Report*, Bethesda, National Institutes of Health, National Institute of Diabetes and Digestive and Kidney Diseases, 2004
 8. Beathard GA, Arnold P, Jackson J, Litchfield T: Physician operators forum of RMS lifeline. Aggressive treatment of early fistula failure. *Kidney Int* 64: 1487–1494, 2003
 9. Faiyaz R, Abreo K, Zaman F, Pervez A, Zibari G, Work J: Salvage of poorly developed arteriovenous fistulae with percutaneous ligation of accessory veins. *Am J Kidney Dis* 39: 824–827, 2002
 10. Beathard GA, Settle SM, Shields MW: Salvage of the non-functioning arteriovenous fistula. *Am J Kidney Dis* 33: 910–916, 1999
 11. Turmel-Rodrigues L, Mouton A, Birmele B, Billaux L, Ammar N, Grezard O, Hauss S, Pengloan J: Salvage of immature forearm fistulas for haemodialysis by interventional radiology. *Nephrol Dial Transplant* 16: 2365–2371, 2001
 12. Corpataux JM, Haesler E, Silacci P, Ris HB, Hayoz D: Low-pressure environment and remodelling of the forearm vein in Brescia-Cimino haemodialysis access. *Nephrol Dial Transplant* 17: 1057–1062, 2002
 13. Wong V, How TV, Ward R, Taylor J, Selvakumar S, Bakran A: Input impedance of radiocephalic arteriovenous fistulae for haemodialysis access: Its value in predicting early failure. *Physiol Meas* 15: 469–480, 1994
 14. Tordoir JH, Rooyens P, Dammers R, van der Sande FM, de Haan M, Yo TI: Prospective evaluation of failure modes in autogenous radiocephalic wrist access for haemodialysis. *Nephrol Dial Transplant* 18: 378–383, 2003
 15. Yerdel MA, Kesenci M, Yazicioglu KM, Doseyen Z, Turkcapar AG, Anadol E: Effect of haemodynamic variables on surgically created arteriovenous fistula flow. *Nephrol Dial Transplant* 12: 1684–1688, 1997
 16. Lin SL, Huang CH, Chen HS, Hsu WA, Yen CJ, Yen TS: Effects of age and diabetes on blood flow rate and primary outcome of newly created hemodialysis arteriovenous fistulas. *Am J Nephrol* 18: 96–100, 1998
 17. Lin SL, Chen HS, Huang CH, Yen TS: Predicting the outcome of hemodialysis arteriovenous fistulae using duplex ultrasonography. *J Formos Med Assoc* 96: 864–868, 1997
 18. Wong V, Ward R, Taylor J, Selvakumar S, How TV, Bakran A: Factors associated with early failure of arteriovenous fistulae for haemodialysis access. *Eur J Vasc Endovasc Surg* 12: 207–213, 1996
 19. Robbin ML, Chamberlain NE, Lockhart ME, Gallichio MH, Young CJ, Deierhoi MH, Allon M: Hemodialysis arteriovenous fistula maturity: US evaluation. *Radiology* 225: 59–64, 2002
 20. Ballermann BJ, Dardik A, Eng E, Liu A: Shear stress and the endothelium. *Kidney Int Suppl* 67: S100–S108, 1998
 21. Girerd X, London G, Boutouyrie P, Mourad JJ, Safar M, Laurent S: Remodeling of the radial artery in response to a chronic increase in shear stress. *Hypertension* 27: 799–803, 1996
 22. Martin AG, Grasty M, Lear PA: Hemodynamics of brachial arteriovenous fistula development. *J Vasc Access* 1: 54–59, 2000
 23. Mulvany MJ, Baumbach GL, Aalkjaer C, Heagerty AM, Korsgaard N, Schiffrin EL, Heistad DD: Vascular remodeling. *Hypertension* 28: 505–506, 1996
 24. Papaioannou TG, Stefanadis C: Vascular wall shear stress: Basic principles and methods. *Hellenic J Cardiol* 46: 9–15, 2005
 25. Zarins CK, Zatina MA, Giddens DP, Ku DN, Glagov S: Shear stress regulation of artery lumen diameter in experimental atherogenesis. *J Vasc Surg* 5: 413–420, 1987
 26. Kamiya A, Togawa T: Adaptive regulation of wall shear stress to flow change in the canine carotid artery. *Am J Physiol* 239: H14–H21, 1980
 27. Langille BL, O'Donnell F: Reductions in arterial diameter produced by chronic decreases in blood flow are endothelium-dependent. *Science* 231: 405–407, 1986
 28. Joannides R, Haefeli WE, Linder L, Richard V, Bakkali EH, Thuillez C, Luscher TF: Nitric oxide is responsible for flow-dependent dilatation of human peripheral conduit arteries in vivo. *Circulation* 91: 1314–1319, 1995
 29. Tohda K, Masuda H, Kawamura K, Shozawa T: Difference in dilatation between endothelium-preserved and -desquamated segments in the flow-loaded rat common carotid artery. *Arterioscler Thromb* 12: 519–528, 1992
 30. Langille BL, O'Donnell F: Reductions in arterial diameter produced by chronic decreases in blood flow are endothelium-dependent. *Science* 231: 405–407, 1986
 31. Tronc F, Wassef M, Esposito B, Henrion D, Glagov S, Tedgui A: Role of NO in flow-induced remodeling of the rabbit common carotid artery. *Arterioscler Thromb Vasc Biol* 16: 1256–1262, 1996
 32. Holtz J, Fostermann JU, Pohl U, Giesler M, Bassenge E: Flow-dependent, endothelium-mediated dilatation of epicardial coronary arteries in conscious dogs: Effects of cyclooxygenase inhibition. *J Cardiovasc Pharmacol* 6: 1161–1169, 1984
 33. Masuda H, Zhuang YJ, Singh TM, Kawamura K, Murakami M, Zarins CK, Glagov S: Adaptive remodeling of internal elastic lamina and endothelial lining during flow-induced arterial enlargement. *Arterioscler Thromb Vasc Biol* 19: 2298–2307, 1999
 34. Tronc F, Mallat Z, Lehoux S, Wassef M, Esposito B, Tedgui A: Role of matrix metalloproteinases in blood flow-induced arterial enlargement: Interaction with NO. *Arterioscler Thromb Vasc Biol* 20: E120–E126, 2000
 35. Paszkowiak JJ, Dardik A: Arterial wall shear stress: Observations from the bench to the bedside. *Vasc Endovascular Surg* 37: 47–57, 2003
 36. Berceci SA, Davies MG, Kenagy RD, Clowes AW: Flow-induced neointimal regression in baboon polytetrafluoroethylene grafts is associated with decreased cell proliferation and increased apoptosis. *J Vasc Surg* 36: 1248–1255, 2002
 37. Butterfield AB, Miller CW, Lumb WV, McLeod FD, Nelson AW, Histan MB: Inverse effect of chronically elevated blood flow on atherogenesis in miniature swine. *Atherosclerosis* 26: 215–224, 1977
 38. Qin F, Dardik H, Pangilinan A, Robinson J, Chuy J, Wengerter K: Remodeling and suppression of intimal hyperplasia of vascular grafts with a distal arteriovenous fistula in a rat model. *J Vasc Surg* 34: 701–706, 2001
 39. Abbruzzese TA, Guzman RJ, Martin RL, Yee C, Zarins CK, Dalman RL: Matrix metalloproteinase inhibition limits ar-

- terial enlargements in a rodent arteriovenous fistula model. *Surgery* 124: 328–334, 1998
40. Sho E, Sho M, Singh TM, Nanjo H, Komatsu M, Xu C, Masuda H, Zarins CK: Arterial enlargement in response to high flow requires early expression of matrix metalloproteinases to degrade extracellular matrix. *Exp Mol Pathol* 73: 142–153, 2002
 41. Kraiss LW, Geary RL, Mattsson EJ, Vergel S, Au YP, Clowes AW: Acute reductions in blood flow and shear stress induce platelet-derived growth factor-A expression in baboon prosthetic grafts. *Circ Res* 79: 45–53, 1996
 42. Singh TM, Abe KY, Sasaki T, Zhuang YJ, Masuda H, Zarins CK: Basic fibroblast growth factor expression precedes flow-induced arterial enlargement. *J Surg Res* 77: 165–173, 1998
 43. Nakahashi TK, Hoshina K, Tsao PS, Sho E, Sho M, Karwowski JK, Yeh C, Yang RB, Topper JN, Dalman RL: Flow loading induces macrophage antioxidative gene expression in experimental aneurysms. *Arterioscler Thromb Vasc Biol* 22: 2017–2022, 2002
 44. Sho E, Sho M, Hoshina K, Kimura H, Nakahashi TK, Dalman RL: Hemodynamic forces regulate mural macrophage infiltration in experimental aortic aneurysms. *Exp Mol Pathol* 76: 108–116, 2004
 45. Beathard GA: An algorithm for the physical examination of early fistula failure. *Semin Dial* 18: 336–342, 2005
 46. Kian K, Vassalotti JA: The new arteriovenous fistula: The need for earlier evaluation and intervention. *Semin Dial* 18: 3–7, 2005
 47. Beathard GA: Angioplasty for arteriovenous grafts and fistulae. *Semin Nephrol* 22: 202–210, 2002
 48. Achkar K, Nassar GM: Salvage of a severely dysfunctional arteriovenous fistula with a strictured and occluded out-flow tract. *Semin Dial* 18: 336–342, 2005
 49. Oakes DD, Sherck JP, Cobb LF: Surgical salvage of failed radiocephalic arteriovenous fistulae: Techniques and results in 29 patients. *Kidney Int* 53: 480–487, 1998
 50. Mickley V, Cazzonelli M, Bossinger A: [The stenosed Brescia-Cimino fistula: Operation or intervention?] *Zentralbl Chir* 128: 757–761, 2003

Functioning vascular access is the lifeline of the hemodialysis patient. Please refer to the Disease of the Month article in the April issue of *JASN* (available online at www.jasn.org) on vascular access to compliment the papers by Nassar *et al.*, Asif *et al.*, and the access data from DOPPS in this issue of *CJASN*.